

PATIENT

Amor Atkins

SPECIES

Canine

BREED

Shih Tzu

SEX

Female Spayed

AGE

12 years

WEIGHT

11lbs

INTERPRETED BY

Maggie Machen Lamy,
DVM, DACVIM
(Cardiology)

IMAGING PERFORMED BY

Dana Alterman,
RDCS, LVT

HOSPITAL NAME

Eubank Animal Clinic

REFERRING VET

Dr. Smith

INVOICE

27199

DATE

10/31/22

PRESENTING CLINICAL SIGNS

History: Increasing loudness of murmur with radiographs suggestive of pulmonary edema. Slight abdominal breathing.

-Current medications: Furosemide 1mg/kg BID.

ELECTROCARDIOGRAPHIC FINDINGS *Note: Single lead ECGs are evaluated as a rhythm strip. Morphology/MEA cannot be definitively commented on.

A single lead ECG is available; 50mm/s, 20mm/mV. The average heart rate is 140bpm (range 130-150bpm). The rhythm is sinus in origin, with a p for every QRS complex and vice versa. The P and QRS are inverted. No ectopic beats, pauses or other dysrhythmias observed. ECG diagnosis: Normal sinus rhythm with respiratory variation.

ECHOCARDIOGRAM FINDINGS

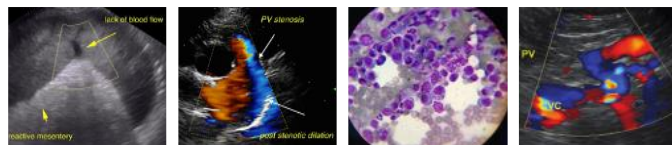
2D, m-mode, color flow and doppler imaging is available. Diffuse thickening of mitral valve leaflets with prolapse into the left atrial lumen. Severe eccentric mitral regurgitation with severe left atrial dilation. Normal MR velocity. Mild LV dilation with hyperdynamic myocardial function. The tricuspid valve appears normal with no TR. Normal right atrial and ventricular diameter and morphology. The pulmonic and aortic valves are normal in morphology and mobility. Normal aortic and pulmonic outflow velocities with laminar flow. Trace AI and no PI. No pericardial or pleural effusion noted. No obvious cardiac masses.

CARDIAC CHART

CANINE CARDIAC PARAMETERS	MR VMAX (m/s)	TR VMAX (m/s)	LA/AO (Boon method)	LA/AO (Heart Base; Swe)	FS (%)	EF (%)	EPSS (cm)
NORMAL PARAMETER	4.5-5.5	<2.7	1.3	<1.6	28-40	40-100	<0.6
PATIENT	4.8	NA	NM	2.2	48	81	NM
CANINE CARDIAC PARAMETERS	HR (BPM)	AV VMAX (m/s)	PV MAX (m/s)	BODY WEIGHT (kg)	LA 2D short axis Base view (cm)	LVIDd Avg; 2D and m-mode short axis (cm)	LVIDs Avg; 2D and m-mode short axis (cm)
NORMAL PARAMETER	50-100	0.7-1.7	0.7-1.6	BELOW	BELOW	BELOW	BELOW
PATIENT	NM	1.2	0.73	5.0	2.5	2.9	1.5
HOSPITAL NAME	*Normal chamber parameters expressed as a mean value (SD)			3	1.27 (5.3)	2.46 (2.46)	1.36 (5.5)
REFERRING VET	BODY WEIGHT DEPENDENT PARAMETERS			5	1.40 (4.5)	2.74 (5.2)	1.60 (4.7)
	*Note: All measurements based upon multi-modal images and methods. An average value is reported.			10	1.50 (3.8)	3.27 (3.5)	2.06 (3.1)
				15	1.83 (2.0)	3.71 (2.4)	2.43 (2.1)
				20	2.02 (1.9)	4.14 (2.2)	2.80 (2.0)
				25	2.18 (2.4)	4.48 (2.9)	3.10 (2.5)
				30	2.33 (3.3)	4.83 (3.9)	3.39 (3.4)
				35	2.48 (4.3)	5.17 (5.0)	3.69 (4.5)
				40	2.62 (5.2)	5.48 (6.1)	3.96 (5.4)
				50	2.88 (7.1)	6.07 (8.3)	4.46 (7.4)

INTERPRETATION OF THE FINDINGS & FURTHER RECOMMENDATIONS

The cause of the murmur is chronic degenerative valve disease causing severe mitral regurgitation. Severe left atrial enlargement indicates the risk for spontaneous congestive heart



PATIENT

Amor Atkins

failure is elevated. A small aortic leak is noted, and a baseline blood pressure is recommended. No additional issues are identified. The ECG is unremarkable with a normal sinus rhythm.

SPECIES

Canine

In light of the clinical signs and severity of disease on echocardiogram, there is suspicion for early congestive heart failure and medications are warranted lifelong as below. Monitoring of sleeping respiratory rates will be paramount to screen for congestive heart failure at home. Cough suppression to improve QOL can also be considered (hydrocodone, 0.2-0.4mg/kg up to q4-6h PRN) for any residual mechanical cough in the face of normal sleeping respiratory rates. The average survival time of canine patients with active pulmonary edema is 8-9 months on medications, however they generally are able to maintain a good quality of life for that period. Patient will always be at risk for recurrent CHF, development of arrhythmias/LA tear, syncope and/or sudden death in the future.

BREED

Shih Tzu

SEX

Female Spayed

Omega fatty acid supplementation and mild salt restriction may also be of some long-term benefit. Monitor for acute progression of the cough, labored breathing, exercise intolerance or collapse episodes in the future.

AGE

12 years

PLAN

Institute Pimobendan 0.3mg/kg PO q12h. Administer Furosemide 1-2mg/kg PO q12h. Institute spironolactone 1-2mg/kg PO q12h.

WEIGHT

11lbs

Monitor SRRs at home. Monitor renal values and BP in 10-14 days, then every 3-4 months while on diuretics. If doing well and BP >130mmHg, institute ACEI 0.5mg/kg PO q12h. Consider hydrocodone if needed for QOL.

INTERPRETED BY

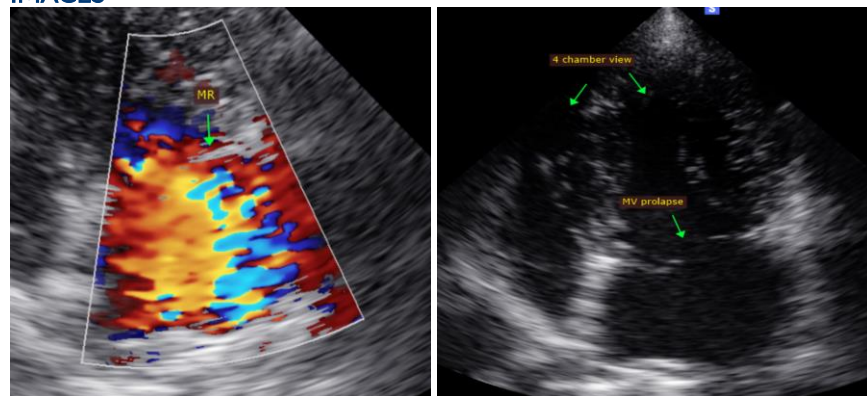
Maggie Machen Lamy,
DVM, DACVIM
(Cardiology)

Recommend conservative monitoring with a recheck echocardiogram in 6 months, sooner if any development of associated clinical signs occurs in the interim.

IMAGING PERFORMED BY

Dana Alterman,
RDCS, LVT

IMAGES



HOSPITAL NAME

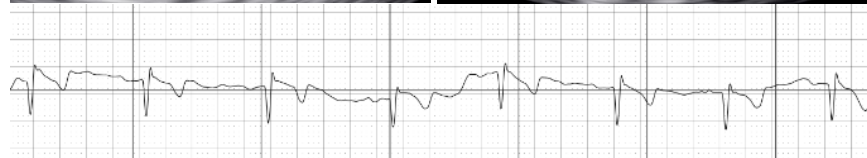
Eubank Animal Clinic

REFERRING VET

Dr. Smith

INVOICE

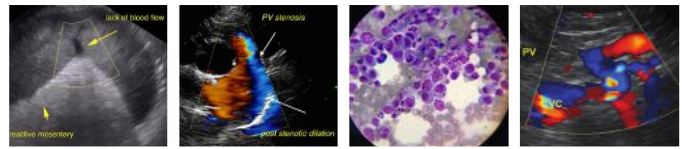
27199



DATE

10/31/22

The information and recommendations provided are based on the images presented by the referring veterinarian. No evaluation can be communicated regarding pathology that was not visible in the image/video clips provided.



PATIENT

Amor Atkins

Thank you for this referral. This report was generated using transcription software, and minor dictation errors may be present. If the clinical or image interpretation does not parallel your findings or if I can be of any further assistance, please contact me.

SPECIES

Canine

Maggie Machen Lamy, DVM

Diplomate of the American College of Veterinary Internal Medicine (Cardiology)

info@sonopath.com

BREED

Shih Tzu

SEX

Female Spayed

AGE

12 years

WEIGHT

11lbs

INTERPRETED BY

Maggie Machen Lamy,
DVM, DACVIM
(Cardiology)

**IMAGING
PERFORMED BY**

Dana Alterman,
RDCS, LVT

HOSPITAL NAME

Eubank Animal Clinic

REFERRING VET

Dr. Smith

INVOICE

27199

DATE

10/31/22